

How to carry out
**Atraumatic Restorative
Treatment (ART)** on decayed teeth
- A Training Manual for Public
Health Workers

Palwasha Momand
Jayanthi Stjernswärd
2008

‘The content of this manual is reproduced from the original ART manual written by Dr. Jo Frencken, Prof Prathip Phantumvanit, Prof Taco Pilot, Dr. Yupin Songpaisan and Dr. Evert van Amerongen and published by the WHO Collaborating Centre for Oral Health Services Research in Groningen, The Netherlands in 1997’

Design and layout by Gisela Ladda Tayanin,
WHO Collaborating Centre

Address for correspondence:
Dr. Jayanthi Stjernswärd
Director, WHO Collaborating Center
Faculty of Odontology, Malmo University
Carl Gustavs Väg 34,
SE-205 06 Malmo,
Sweden

E-mail: Jayanthi.Stjernsward@mah.se

- Contents -

A traumatic Restorative Treatment (ART).....	4
I nstruments and materials essential for ART.....	5
S election of teeth with carious cavities suitable for ART.....	8
W ork posture and position.....	9
P reparing the mouth.....	11
P reparing the cavity.....	12
C leaning the prepared cavity.....	13
M ixing the glass-ionomer filling material.....	13
P rocedure for restoring one-surface cavities step-by-step.....	14
P rocedure for restoring multiple-surface cavities step-by-step.....	15
H ygiene and control of cross infection	16
C leaning and sterilizing instructions.....	16
R eferences.....	17
A cknowledgement.....	17
S ome examples of ART programmes (2008)	18
A. Brazil	19
B. South Africa	21
C. Sri Lanka	22
D. Turkey	23

Atraumatic Restorative Treatment (ART)

Atraumatic Restorative Treatment (ART) is a preventive and restorative approach for managing carious lesions of the teeth. It constitutes of hand instruments only (no electric drills used) for widening cavity openings and for excavating soft decayed tissue from within the cavity, followed by the application of an adhesive dental material, usually a high-viscosity glass-ionomer filling material, into the cavity and over the adjacent pits and fissures. This treatment approach has the advantages of being relatively easy to use after proper training and has shown to be cost-effective. It also hardly induces dental anxiety amongst children and adults. Additionally, ART does not require extensive dental equipment. The instruments and materials needed to perform ART are portable. ART can be implemented by properly trained personnel with even non-dental background. ART offers an opportunity for preventive and restorative dental treatment under field conditions where there is lack of electricity and modern dental facilities.

It is a well-documented fact that caries among children in the developing world often goes untreated due to lack of manpower, resources and infrastructure. This Training Manual is aimed for Public Health Workers and non-dental health personnel who could be trained to perform ART mainly on children with decayed teeth who otherwise will never receive treatment. This hopefully will encourage countries to train Community or Public Health Workers who then can carry out ART fillings in Schools, villages or refugee camps where there are not enough or no dentists at all. However, studies have shown that a proper training in ART and caries prevention is required before non-dental health personnel are able to confidently apply ART. Periodical close supervision at the participants working station by the trainer(s) is mandatory. ART alone is just one aspect of good oral health. The other main aspect is oral hygiene that is achieved through daily tooth brushing with a fluoridated toothpaste.

Instruments and Materials essential for ART

Instruments

- A. **MOUTH MIRROR** (Fig. 1) – to look inside the mouth

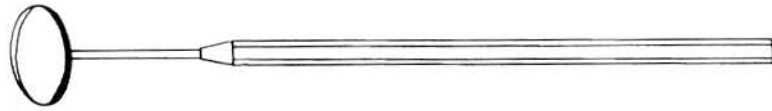

Fig. 1

- B. **EXPLORER/PROBE** (Fig. 2) – for identification where soft carious dentine is present. **DO NOT** poke the point into very small carious lesions. **DO NOT** probe into deep cavities.



Fig. 2

- C. **PAIR OF TWEEZERS** (Fig. 3) - used for carrying cotton wool rolls from the tray to the mouth and back.

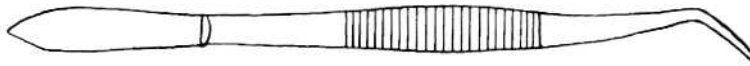

Fig. 3

- D. **SPOON EXCAVATOR** (Fig. 4-5) – is used for removing soft carious dentine.

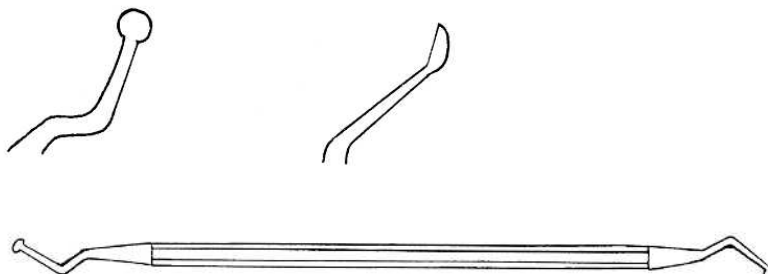


Fig. 4, 5

E. **DENTAL HATCHET** (Fig. 6) – is used for widening the entrance to the cavity.




Fig. 6

F. **APPLIERS/CARVER** (Fig 7) – the blunt end is used for inserting the mixed glass-ionomer into the cleaned cavity. The sharp end is designed to remove excess filling material and shape the filled cavity.



Fig. 7

G. **MIXING-PAD and SPATULA** (Fig. 8) – are necessary for mixing glass-ionomer filling material.

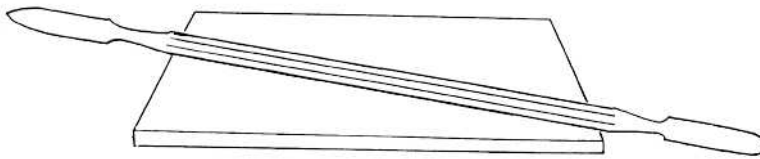


Fig. 8

Materials

Besides the glass-ionomer filling material, there are few other essential materials necessary to carry out ART.

A. **COTTON WOOL ROLLS** (Fig. 9) – absorption of saliva so that the tooth can be kept dry.

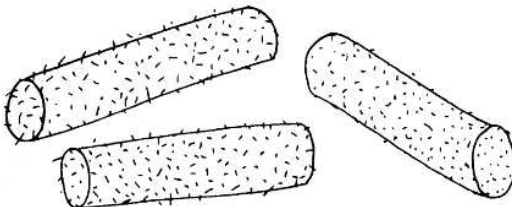


Fig. 9

B. COTTON WOOL PELLETS (Fig. 10) – used for cleaning cavities.




Fig. 10

C. PETROLEUM JELLY – used to keep moisture away from the glass-ionomer filling and to prevent the examination glove from sticking to the filling material as it sets.

D. PLASTIC STRIP (Fig. 11) – used for contouring the surface on the side of the tooth of multiple-surface restorations.

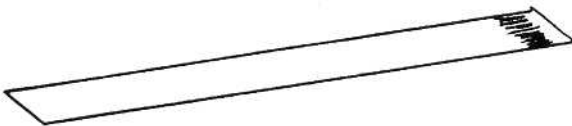


Fig. 11

E. WEDGES (Fig. 12) – used to hold the plastic strip close to the shape of the surface on the side of a tooth so that restorative material is not forced between the gums and teeth.

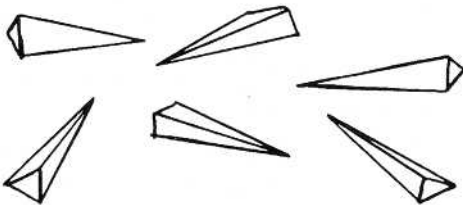


Fig. 12

FILLING MATERIAL

A. GLASS-IONOMER (Fig. 13) - The material used for filling cavities is glass-ionomer. It comes as a powder and a liquid form that has to be mixed together.

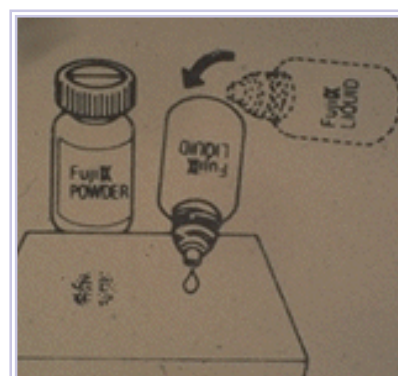


Fig. 13

B. DENTINE CONDITIONER – To improve the chemical bonding of glass-ionomer filling material to the tooth cavity surface, the cavity walls are coated with a dentine conditioner.

Selection of Teeth with Carious Cavities Suitable for ART

Recognizing Dental Caries (Fig. 14)

A breakage in the tooth surface or a cavity in the tooth is recognized as decayed or carious tooth.

With the probe (fig. 2), gently and carefully go into the cavity, which will feel softer and may even be quite mushy.

The colour will vary from pale yellow in a new cavity to dark brown if it has been there a longer time.

Remember that just a change of the tooth surface does not necessarily mean it is caries.

Sometimes, however, teeth can be discolored not because of dental caries, but because of staining due to some foods.

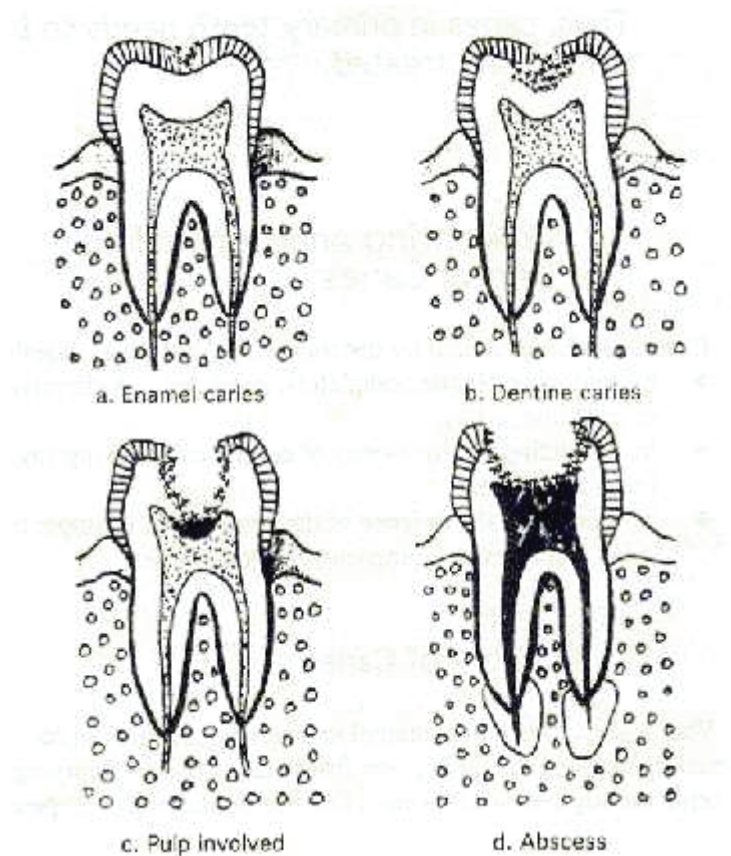


Fig. 14

ART can be carried out when:

- there is a cavity/hole in the tooth.
- the hole can be reached with your instruments.

ART should not be used when:

- there is presence of swelling (abscess) or pus or fluid coming out (opening from abscess to the oral cavity) near the carious tooth,
- the hole is too deep (so that the core/pulp of the tooth is exposed),
- teeth have been painful for a long time and there may be chronic infection of the pulp of the tooth,
- there is an obvious carious cavity, but the opening cannot be reached by your hand instrument,
- there are clear signs of a cavity, for example on the side of a tooth, but the cavity cannot be entered from the side or from the top of the tooth direction.

Work posture and positions (Fig. 15-17)

Operator's position (Your Position)

- Operator should sit firmly on the stool, with a straight back, thighs parallel to the floor and both feet flat on the floor.
- The height of the stool should be adjusted so that the operator can see the patient's teeth clearly.

Oral care is best provided by a team consisting of an operator and an assistant. However, assistance may not always be available. The assistance works at the left side of a right-handed operator and does not change position.

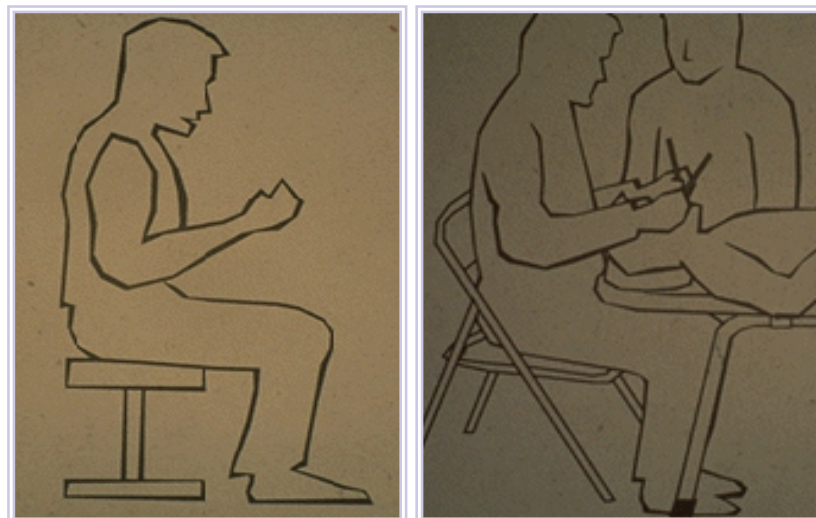


Fig. 15, 16 Operator's posture

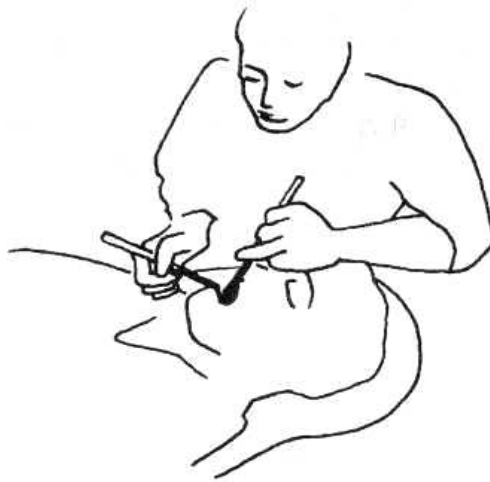

Fig. 17 Operator's position

Patient's position (Fig. 18)

- The patient should lie on a flat surface that will provide safe and secure body support and a comfortable and stable position for lengthy periods of time.

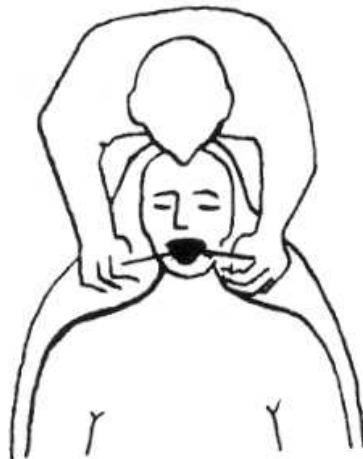

Fig. 18 Patient's position

Patient's head position (Fig. 19)

- Backward tilt lifting the chin for access to upper teeth (a).
- Forward tilt dropping the chin for access to lower teeth (b).




Fig. 19

Preparing the mouth (Fig. 20-21)

An important aspect for the success of ART is the control of saliva around the tooth being treated. Cotton wool rolls (fig. 9) are quite effective at absorbing saliva and can provide short-term protection from moisture/saliva.

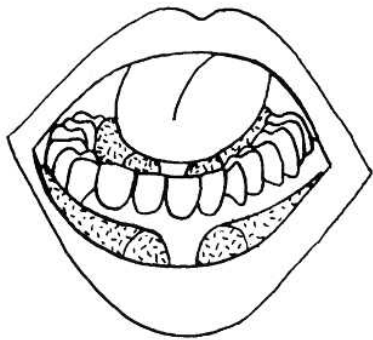

Fig. 20 For teeth in the lower jaw

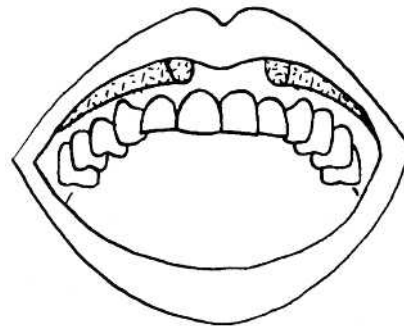


Fig. 21 For teeth in the upper jaw

Preparing the cavity (Fig. 22)

- Place cotton wool rolls alongside the tooth to be treated to absorb saliva and keep tooth dry.
- Soft caries is removed using the excavator (figs. 4, 5) by making circular scooping movements - like using a spoon.
- If the opening of the hole is narrow, widen the entrance of the cavity by placing the blade of the dental hatchet (fig. 6) into the cavity and turning the instrument forward and backward like turning a key in a lock.
- Excavation is easy to do when the tooth is dry. Therefore, change saturated cotton wools for dry ones.

After all the caries is removed from the cavity, it is cleaned with wet cotton wool

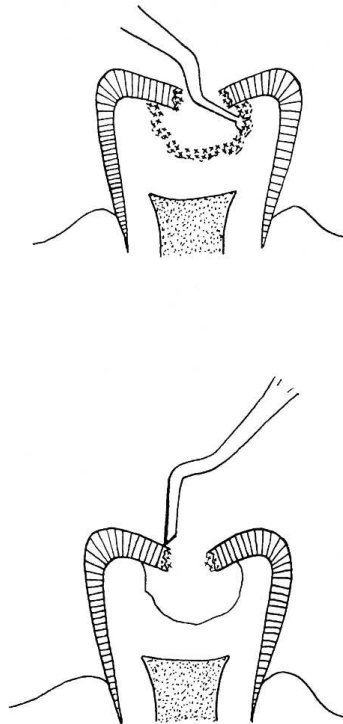


Fig. 22 Caries removed by excavator (above), widen cavity entrance with hatchet (below).

Cleaning the prepared cavity (Fig. 23)

In order to improve binding of the material to the tooth surface, the cavity walls must be made clean. The surface is therefore cleaned with dentine conditioner.

- Apply one drop of conditioner on a mixing pad or slab.
- Hold a cotton wool pellet with a pair of tweezers (fig. 2) and dip it in the drop and then clean the entire cavity for 10-15 seconds.
- Then immediately wash the cavity at least twice with cotton wool pellets, dipped in clean water.
- Dry the cavity with dry cotton wool pellets.

If the cavity is contaminated with blood, stop the bleeding by pressing with a cotton wool pellet on the wound. Wash the blood away from the cavity. Then clean the cavity as described above.

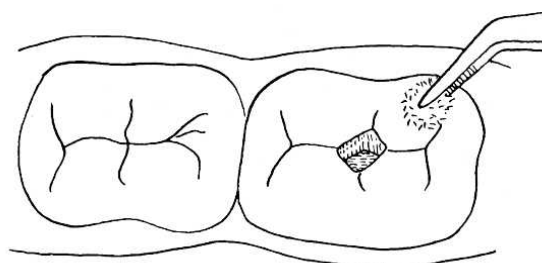


Fig. 23

Mixing the glass-ionomer filling material (Fig. 24)

Follow the instruction according to the manufacturer. Place a scoop of the powder on a mixing pad (fig. 8). Use the spatula (fig. 8) to divide the powder into two equal portions, and then put a drop of liquid next to the powder. Spread liquid on the mixing pad with the spatula and start mixing by adding one half portion of the powder into the liquid. As soon as the powder particles are wetted the second portion of the powder is included into the mixture. Mixing should be completed within 20-30 sec. Final mixture should look smooth.

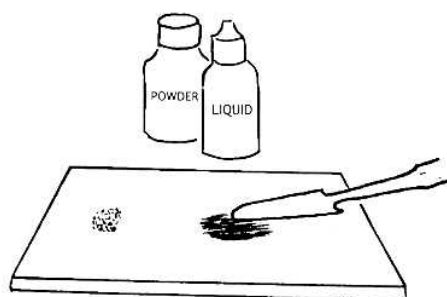


Fig. 24

Procedure for restoring one-surface cavities step-by-step (Fig. 25 a – d)

- Check that all instruments and materials are available and ready for use.
- Ensure that the tooth is kept dry during the filling.
- Prepare the cavity as mentioned above.
- Mix the filling material as described above.
- Insert immediately the mixture in small amounts into the cavity using the blunt blade of the applier/carver (fig. 7). Use round surface of an excavator to push the mixture into deeper parts of the cavity. (a.)
- Rub some petroleum jelly on the gloved index finger.
- Place the index finger on the restorative material, press and remove finger sideways after a few seconds. (b.)
- Remove visible excess of glass-ionomer with a medium or large excavator.
- Wait 1-2 minutes till the material feels hard, whilst keeping the tooth dry.
- Use the carver to make sure that the filling is not high but is flushed to the surface of the tooth. (c.)
- Apply a new layer of petroleum jelly over the filling to protect it from getting wet by saliva.
- Remove cotton wool rolls from the mouth.
- Ask the patient not to eat for at least one hour.

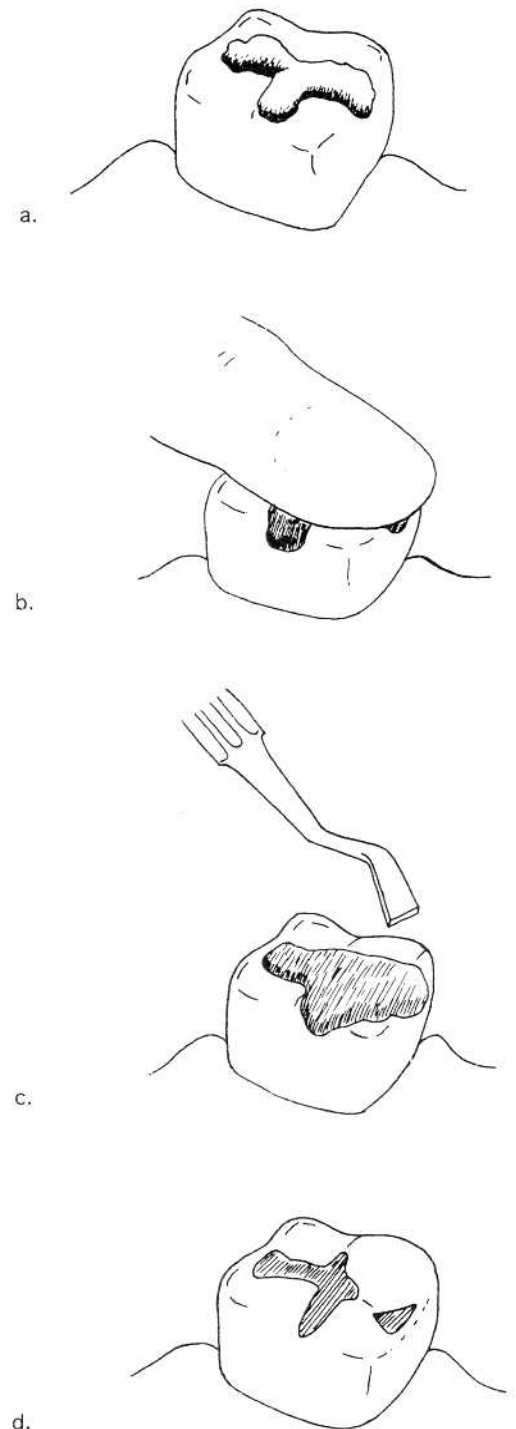


Fig. 25

Procedure for restoring multiple-surface cavities step-by-step

(Fig. 26-28)

- Work in a dry mouth environment using cotton wool rolls. Replace these when required.
- Clean the cavity and ensure that the outline is smooth and free of caries.
- Place a plastic strip (fig. 11) around the tooth that is being restored.
- Insert a soft wooden wedge (fig. 12) between the teeth just at the gum margin to keep the plastic strip firmly in position.
- Clean the cavity as described earlier.
- Mix the glass-ionomer as described before and insert it into the cavity until it is slightly overfilled.
- Hold the plastic strip tightly with the index finger and thumb.
- When the filling has set, remove the wedge and strip and cover the filling with petroleum jelly.
- Remove any excess filling with the carver, check the height of the filling and apply another coat of petroleum jelly.
- Remove cotton wool rolls from the mouth.
- Ask the patient not to eat for an hour.

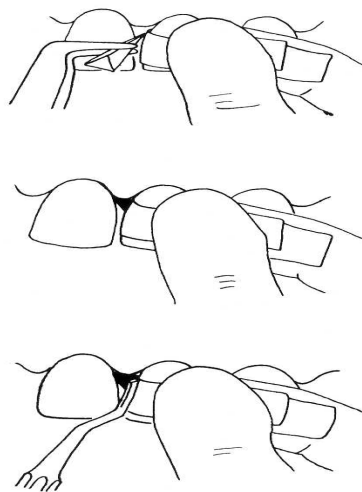

Fig. 26 Inserting wedge and using plastic strip to fill front tooth

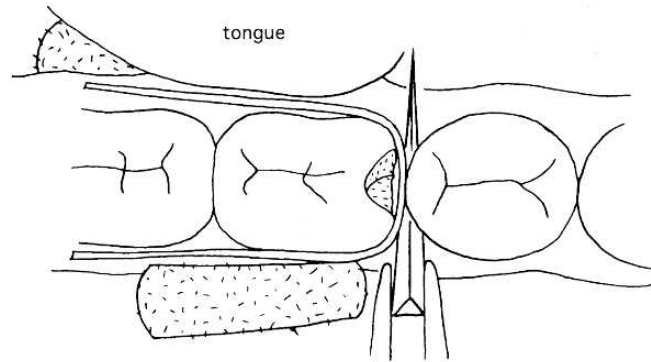


Fig. 27 Plastic strip and wedge in place for a molar filling.

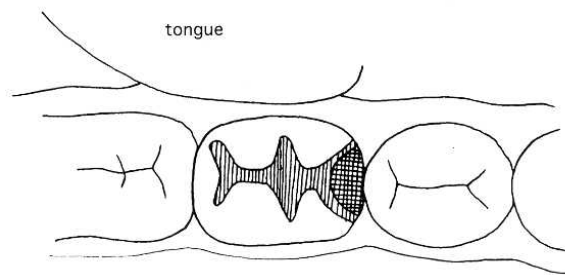


Fig. 28 Finished restoration of molar tooth.

Hygiene and control of cross infection

If available, always wear gloves and mask. Cleaning and disinfection of the working place and sterilization of instruments is essential to prevent infection passing from operator to patient and vice versa or between patients via the operator.

Cleaning and sterilizing instructions

- Place all instruments in water immediately after use.
- Remove all debris from the instruments by scrubbing with brush in soapy water.

If an autoclave is available, follow the manufacturer's instructions carefully. If a pressure cooker is available, the instructions presented below are useful.

In a field situation:

- Prepare fire using the fuel available - wood, gas, charcoal, solar energy.
- Put the clean instruments in a pressure cooker and add clean water to a depth of 2- 3cm from the bottom.

(Read instructions supplied with the pressure cooker)

- Place the pressure cooker on the stove and bring to boil. When the steam comes out from the vent, put the weight in place.
- Continue heating the pressure cooker on low heat for a minimum of 15 minutes. If available, set a timer for 15 minutes.
- Ensure that steam continues to be released from the pressure cooker during this time. If this stops, there may be no water left in the pressure cooker anymore. If this happens remove the pressure cooker from the heat, add water and repeat the cycle.

Take care when opening the pressure cooker. Release the pressure first.

- Remove the pressure cooker from stove after 15 minutes, and leave it to cool. Take instruments out of pressure cooker with instrument forceps and dry them with a clean towel.
- Store them in a covered, preferably, metal box

If a pressure cooker is not available, instruments can be sterilized in a pan. Use a pan with a lid and boil them in water for a minimum of 30 minutes. Remove the instruments with instrument forceps immediately and dry them with a clean towel. Store the instruments in a covered, preferably metal box.

References

1. Frencken J, Phantumvanit P, Pilot T, Songpaisan Y, Amerongen E. Manual for the Atraumatic Restorative Treatment approach to control dental caries. WHO Collaborating Centre for oral health services research, Groningen, Netherlands, 1997. (http://www.dhin.nl/art_manual___main.htm) 2008
2. WHO Oral Health Country/Area Profile Programme (CAPP) (<http://www.whocollab.od.mah.se/expl/artintrod.html>), 2008

Acknowledgement

We wish to extend our sincere thanks and appreciation to Prof Jo Frencken, International Centre for Oral Health, Nijmegen, Netherlands, for giving us permission to use the illustrations from the “Manual for the ART approach to control dental caries” for this presentation.

Examples of ART programmes from different countries presented in the WHO Oral Health database (2008)

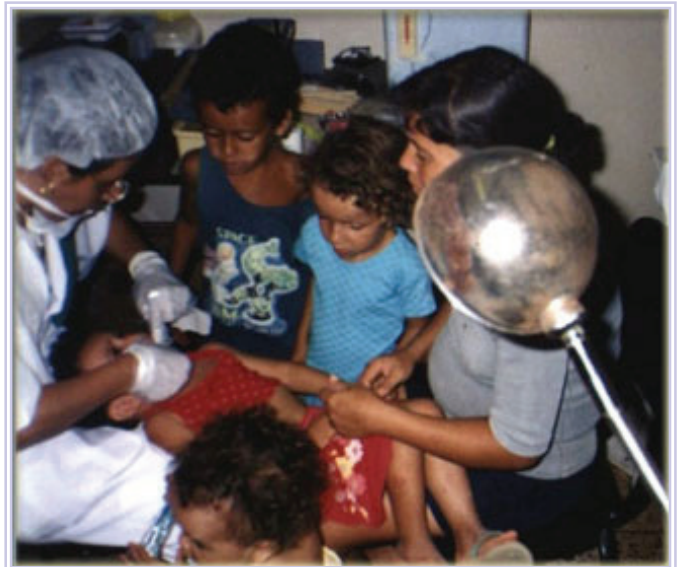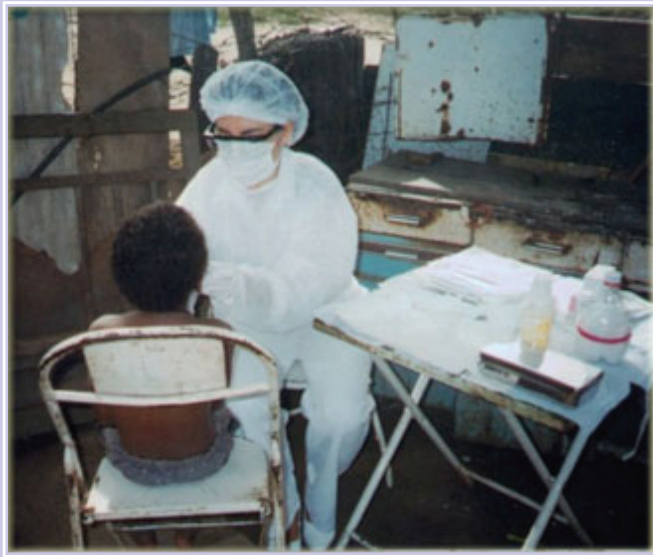- Brazil
- South Africa
- Sri Lanka
- Turkey

Brazil

Atraumatic Restorative Treatment (ART) for a disadvantaged Brazilian Community: (<http://www.whocollab.od.mah.se/amro/brazil/data/brazilart.html>)



“Training oral health personnel In October 2001, three oral health teams were included in the Family Health Programme in this area. These teams and other dentists in the public health network were trained by a university teacher in the area, to perform ART restorations using glass ionomer cement.”



Source: Isolda Cerqueira Cruz, Débora Abreu Badaró, Manoel Damásio Machado Neto, Márcia Cançado Figueiredo, Mircelei Saldanha Sampaio and Andréa Centeno Rosa. Two-year Evaluation of Atraumatic Restorative Treatment (ART) in a Brazilian Disadvantaged Communities. IADR meeting, Baltimore, 2005, poster # 3039.

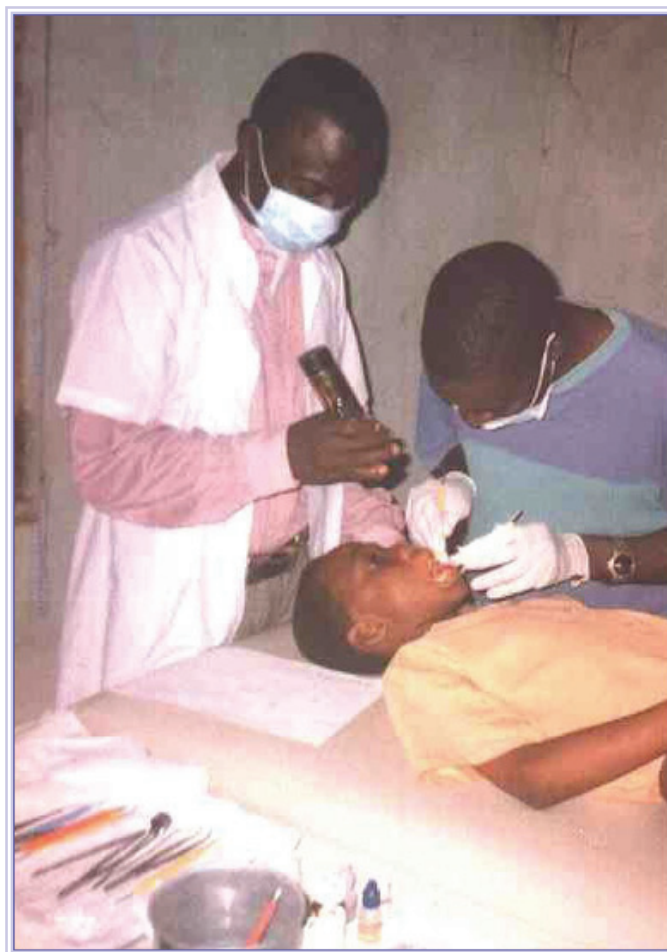
South Africa

Introducing the Atraumatic Restorative Treatment (ART) approach in South Africa: Activity Report (<http://www.whocollab.od.mah.se/expl/artsa.html>)

“Refugee Services:

In 1997, twelve lay refugees in the Liberian refugee camp were trained in basic oral health care including ART according to WHO training module. This primary oral health programme for refugees were revisited after 3 years in December 1999.

The 12 trained refugees maintained an oral health clinic in the camp, where patients were treated with ART”.



Source: Mickenautsch S. and Rudolph MJ. Implementation of the ART approach in South Africa: An activity report, SADJ 2001; 56: 327-329.

Sri Lanka

Atraumatic Restorative Treatment (ART) Programme in Sri Lanka: (<http://www.whocollab.od.mah.se/searo/srilanka/data/srilankaart.html>)

“Once a month a team of dentists and about 10 dental students from the Division of Community Dentistry visit a primary school in the Kandy area. The Faculty receive requests from the Principals of schools, mainly from impoverished areas where the schoolchildren otherwise will not receive any dental care. The students supervised by the doctors, carry out the examination and treatment in a well-lit classroom or outside in the school premises. While the children are waiting for treatment, they are given oral health education by the dental students. ART is carried out on about 25-30 children on one visit. Around 250 students are provided with ART per year”.

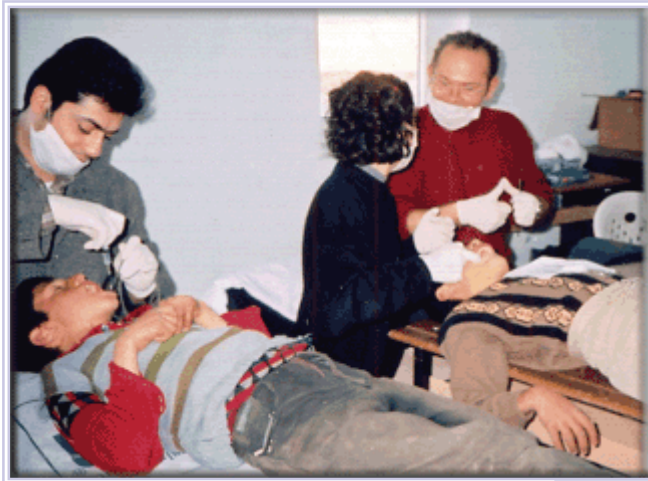

ART being carried out

Turkey

Atraumatic Restorative Treatment (ART) Programme in some rural areas of Turkey: (<http://www.whocollab.od.mah.se/euro/turkey/data/turkeyart.html>)

“Dentists and often dental students visit the rural areas including Bagivar, a small town and Anatolia. ART restorations are performed in school children, farm worker's children living in tents or children working in cotton fields”.



ART in the field

Source: Dulgergil CT. et al. ART: Is it an efficacious filling technique or an effective preventive measure in rural districts? *Journal of Marmara University Dental Faculty*, 2000; 2: 123-129.

- End -